

# OVERVIEW

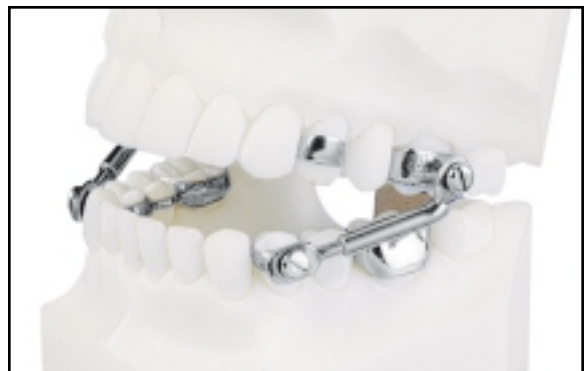## Intra-Arch Maxillary Molar Distalization Appliances for Class II Correction

ROBERT G. KEIM, DDS, EDD, PHD  
CHERYL BERKMAN, DDS, MS

*(Editor's Note: In this quarterly column, JCO provides a brief overview of a clinical topic of interest to orthodontists. Contributions and suggestions for future subjects are welcome.)*

About a third of all orthodontic patients are treated for Class II malocclusions.<sup>1,2</sup> These patients represent a heterogeneous population, with many different etiologies accounting for similar intraoral and extraoral manifestations.<sup>3</sup> Because there is no single mechanical option that can be applied to every Class II patient, it is critical to diagnose and plan these cases on an individual basis. According to McNamara and Brudon, "Each treatment approach differs in its effect on the skeletal structures of the craniofacial region, sometimes accelerating or limiting the growth of the various structures involved."<sup>4</sup>

Considerable research has been devoted to the various options for treating a Class II maloc-



**Fig. 1** Herbst appliance (photo courtesy of Dentaurum, Inc.).

clusion. In fact, it has been estimated that in the decade of the 1980s alone, more than 130 articles were published on Class II treatment, providing information on 14 different appliance systems or approaches.<sup>5</sup> Many more papers have been published since 1990.

Although headgear and various functional appliances have been the mainstay of Class II treatment from the time of Kloehn<sup>6</sup> and Balters,<sup>7</sup> the idea that any one treatment modality can address such a multidimensional problem is naive at best. Kloehn-type headgears are an excellent source of anchorage for holding the maxilla back while allowing the mandible to come forward,<sup>8-10</sup> but their Achilles' heel has always been patient compliance. Many practitioners have simply given up trying to get patients to wear headgear.

Functional appliances that position the mandible forward into a Class I position work well in growing patients whose etiology involves a retrognathic mandible. Many of these appliances—usually variations on the century-old Herbst\* device (Fig. 1)—do not depend on pa-



**Dr. Keim**



**Dr. Berkman**

Dr. Keim is Editor of the *Journal of Clinical Orthodontics*, 1828 Pearl St., Boulder, CO 80302; e-mail: rkeim@usc.edu. Dr. Berkman is a recent graduate of the Advanced Program in Orthodontics, University of Southern California, and is in the private practice of orthodontics in Columbus, OH.

\*Registered trademark of Dentaurum, Inc., 10 Pheasant Run, Newtown, PA 18940.

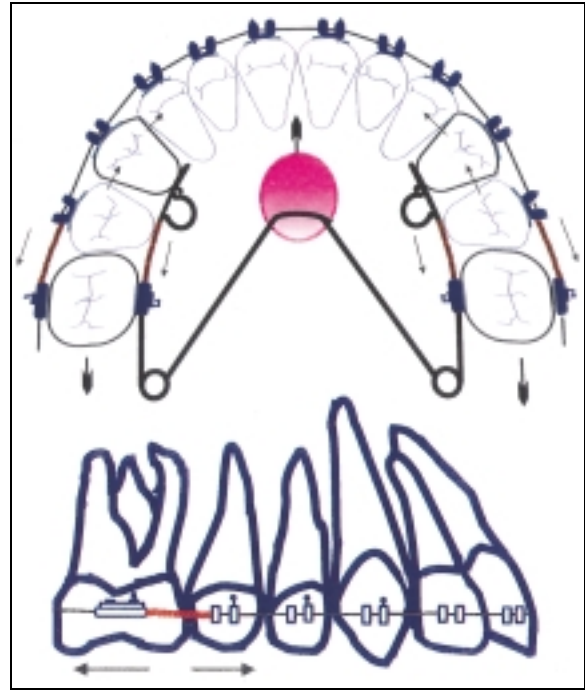
tient cooperation. Not every Class II, however, is due to a retrognathic mandible. Some 10-15% are caused by protrusive maxillae.<sup>11</sup> In such a case, hyperpropulsion of the mandible is simply the wrong solution to the problem. What is actually needed is distalization of the maxillary dental-alveolar structures. Fortunately, a number of intra-arch distalization appliances that do not depend on patient compliance are now available.

**Springs and Wires**

Perhaps the simplest, cheapest, and oldest of these devices is the compressed-coil spring. Although stainless steel and nickel titanium coil springs have been used in conjunction with Nance appliances to successfully distalize maxillary molars since the early part of the 20th century,<sup>11,12</sup> only a few clinical trials have specifically examined their effectiveness in Class II treatment.<sup>13</sup>

Gianelly and colleagues recommended placing nickel titanium coil springs on .016" × .022" stainless steel sectional wires from first premolar to first molar.<sup>14</sup> When compressed, each coil produces approximately 100g of force to move the molar distally along the wire. A Nance appliance extending across the palate between the first premolars acts as an anchorage unit, and an .018" uprighting spring is placed in the vertical slot of each premolar bracket. The authors reported that with 8-10mm of activation, the 100g coils can distalize maxillary molars 1.5mm/month, with approximately 20% anchorage loss. If more activation is needed, a Gurin lock can be used to augment the coil compression. Supplemental mechanics are indicated if excessive anchorage loss is observed. Gianelly advocated using this mechanotherapy in the mixed dentition, before second molar eruption, for maximum distalization.<sup>15</sup>

In 1998, Miura and colleagues compared the properties of Japanese NiTi springs to those of traditional stainless steel coils.<sup>16</sup> They found that the nickel titanium springs exhibited superior springback and elastic properties, as well as an extended range of constant, light, and continuous

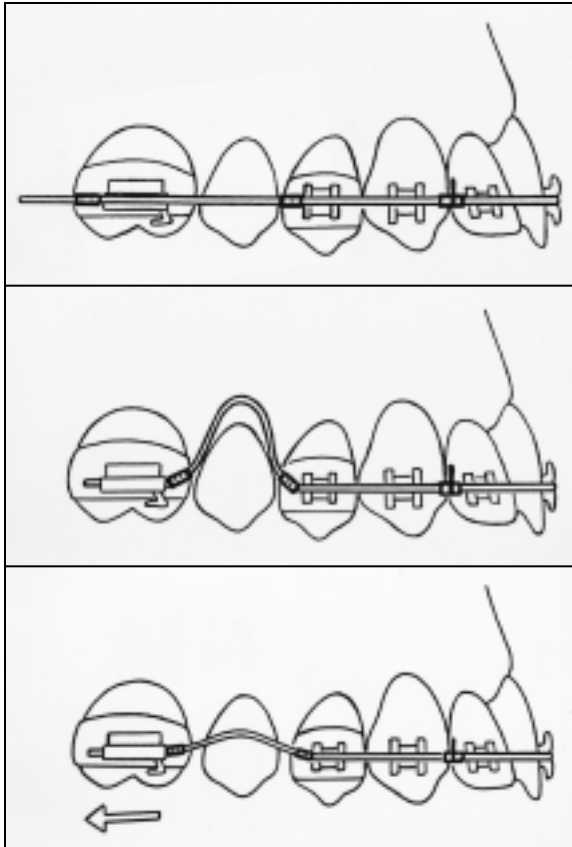


**Fig. 2 Modified Nance appliance combined with nickel titanium coil springs.<sup>20</sup>**

force. The force of the springs could easily be controlled by changing the diameter, the size of the lumen, and the martensitic transformation temperature.

Coils have also been utilized for unilateral Class II correction. In 1992, Reiner fit 12 patients with a modified Nance appliance, resembling a Quad Helix\*\* with a unilateral lingual open-coil spring, and reported .19mm of maxillary molar distalization per week.<sup>17</sup> Similarly, Keles studied unilateral molar distalization in a group of 15 patients.<sup>18</sup> Using a Nance button, an anterior bite plate, and nickel titanium coil springs acting toward the center of resistance of the maxillary first molars, he was able to move the Class II molars an average of 4.9mm distally in 6.1 months. Anchorage loss was measured as a 1.3mm mesial migration of the first premolars, a 1.8mm increase in incisor protrusion, a 3.2° increase in incisor proclination, and a 2.1mm

\*\*RMO Inc., P.O. Box 17085, Denver, CO 80217.



**Fig. 3** Superelastic nickel titanium wire used to move maxillary molars distally.<sup>21</sup>

increase in overjet.

Other authors have modified the Nance appliance or used different configurations of coil springs to effect distalization within the maxilla<sup>19,20</sup> (Fig. 2). Pieringer and colleagues reported maxillary molar distalization ranging from 1.8mm to 10.5mm, with associated distal tipping of 5.2-22.2°.<sup>19</sup> They concluded that complex three-dimensional movements occurred during distalization, and that the amount of distal movement and the duration of treatment could not be correlated with the pre-existing amounts of tipping, rotation, or incisor protrusion.

Although not as popular as compressed-coil springs, compressed wires have also been adapted for molar distalization. Locatelli and colleagues described the use of a superelastic

nickel titanium wire (NeoSentalloy<sup>\*\*\*</sup>) to move maxillary molars distally<sup>21</sup> (Fig. 3). By placing crimpable stops mesial and distal to a compressed section of wire, it was possible to generate 100g of distal pressure against the maxillary molar, causing a distalization comparable to that achieved with magnets or superelastic nickel titanium coil springs.

Gianelly advocated the use of NeoSentalloy wires and Sentalloy<sup>\*\*\*</sup> coils, coupled with a modified Nance appliance, in his textbook on the Bidimensional technique.<sup>22</sup> With 100g of constant force applied by the coils, .018" × .025" sectional or continuous nickel titanium archwires could effectively distalize the maxillary molars. Gianelly reported .5mm of distal movement per month, although he cited individual variations and the need to overcorrect molar relationships by 2mm.

Kalra bent a TMA<sup>†</sup> wire into what he called a K-loop for more control over moment-to-force ratios in molar distalization.<sup>23</sup> He argued that this compressed wire segment between the first molar and first premolar, in conjunction with a Nance button, would produce more translatory movement than tipping of the molar.

### Jones Jig

The Jones Jig<sup>‡</sup> uses an open-coil nickel titanium spring to deliver 70-75g of force over a compression range of 1-5mm, with a modified Nance appliance attached to the first premolars, second premolars, or primary second molars. After successful distalization of the maxillary posterior segments with minimal anchorage loss, Jones and White concluded that the Jones Jig is "a predictable, rapid, and painless method of correcting Class II relationships without the necessity of patient cooperation".<sup>24</sup> They reported that rotated Class II cases could be treated in 90-120

<sup>\*\*\*</sup>Trademark of GAC International, Inc., 355 Knickerbocker Ave., Bohemia, NY 11716.

<sup>†</sup>Registered trademark of Ormco/"A" Company, 1717 W. Collins Ave., Orange, CO 92867.

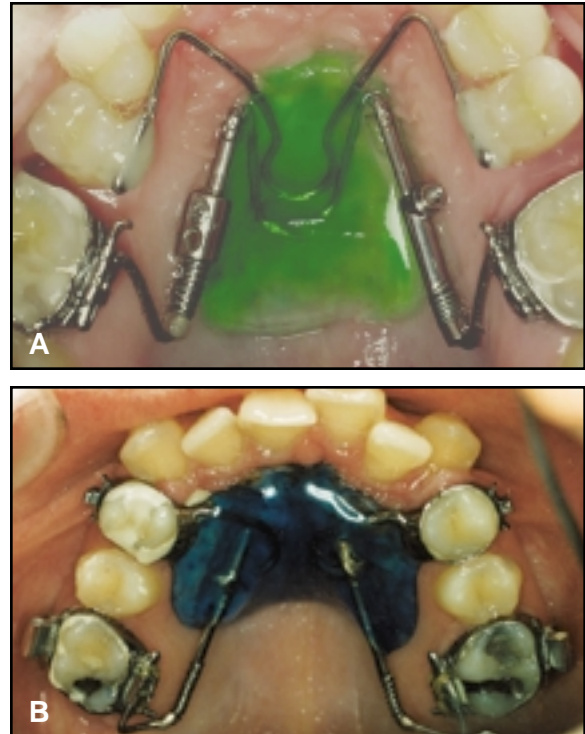
<sup>‡</sup>American Orthodontics, 1714 Cambridge Ave., Sheboygan, WI 53082.

days, and severe Class II molar corrections in 120-180 days. This appliance is designed to be used in conjunction with any other mechanotherapy. Jones and White cautioned, however, that patients with fully bonded maxillary appliances tended to show an initial forward movement of the anterior teeth compared to patients who were treated only with the Jones Jig and Nance appliance.

Because the Jones Jig's line of force application lies occlusally and buccally to the center of resistance of the teeth, it has been shown to produce tipping and rotation of the maxillary molars.<sup>12,25-27</sup> A study by Brickman and colleagues evaluated the long-term effects of the appliance after final debonding<sup>27</sup> (previous authors had only measured the results before and after distalization<sup>25,26</sup>). Compared to a sample population treated with headgear, the Jones Jig tipped the maxillary first molar 7.5° distally and the maxillary second premolar 4.5° mesially, while moving the maxillary first molar 2.5mm distally and the maxillary second premolar 2mm mesially. Brickman and colleagues found that the Jones Jig sample showed no statistical difference from the matched headgear sample when the maxillary molars and incisors were evaluated post-treatment, but attributed this result to self-uprighting of the molars, premolars, and incisors with the placement of full orthodontic appliances. Like Haydar and Üner,<sup>26</sup> they advised using extraoral traction (J-hook headgear) or Class II elastics in conjunction with the Jones Jig for anchorage control. They concluded, "Treatment with the Jones Jig offers the practitioner a nonextraction treatment modality for Class II malocclusion that minimizes patient compliance yet delivers final results consistent with known treatment modalities, including cervical headgear."<sup>27</sup>

### Distal Jet

The Distal Jet<sup>‡</sup> is another intra-arch "non-compliance" device, designed by Carano and Testa in 1996 for distal movement of maxillary molars without the undesirable molar crown tip-

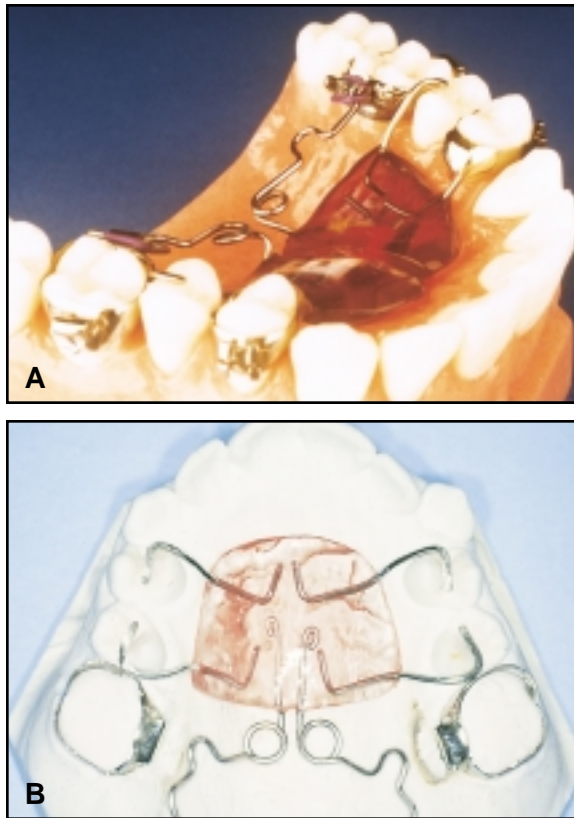


**Fig. 4 A. Distal Jet (original version on patient's right side, simplified version on left).<sup>33</sup> B. Modified Distal Jet.<sup>32</sup>**

ping associated with other appliances.<sup>28</sup> The Distal Jet consists of bilateral lingual tubes attached to an acrylic Nance button and to the second premolars and first molars (Fig. 4). A coil spring and screw-clamp are slid over each tube, and the spring is reactivated by sliding the clamp closer to the first molar on a monthly basis. Once distalization is complete, the appliance can easily be converted to a Nance retainer.

Carano and Testa claimed that the rate of molar movement with the Distal Jet was similar to that with the Jones Jig, but that their appliance did not significantly tip or rotate the molars, and that the anterior anchorage unit remained relatively stable during treatment.<sup>28</sup> Others have confirmed these findings.<sup>1</sup> McNamara and Brudon agreed that the Distal Jet has advantages including less lingual movement and tipping of the molars, improved esthetics and comfort, and easy convertibility to a Nance holding arch after





**Fig. 5 A. Pendulum appliance.<sup>37</sup> B. Modified Pendulum appliance.<sup>44</sup>**

distalization.<sup>11</sup> On the other hand, since the force of the Distal Jet is applied palatally, rotational control can be difficult, and mesial rotation of the maxillary first molars is a common finding.<sup>12</sup>

Several modifications have been made to augment the efficiency and versatility of the original Distal Jet.<sup>29-33</sup> One such variation used a palatal implant in place of the Nance button for anchorage control.<sup>34</sup> Combining the Distal Jet with the Jasper Jumper<sup>‡</sup> has also become an effective means of Class II correction.<sup>35,36</sup>

### Pendulum Appliance

The Pendulum appliance,<sup>†</sup> introduced by

<sup>‡</sup>American Orthodontics, 1714 Cambridge Ave., Sheboygan, WI 53082.

<sup>†</sup>Ormco/“A” Company, 1717 W. Collins Ave., Orange, CO 92867.

Hilgers,<sup>37,38</sup> is unique in that it does not rely on coil springs for its action. Instead, .032" TMA springs deliver a continuous force against the maxillary first molars (Fig. 5). Four occlusal rests extending from the anterior acrylic are either banded or bonded to the first and second premolars, and a large palatal Nance button is used for anchorage. According to Hilgers, “the appliance produces a broad, swinging arc—or pendulum—of force from the midline of the palate to the upper molars.”<sup>37</sup> A lingual force is thereby placed upon the molars; to prevent a crossbite from developing, an expansion screw can be added to the appliance (the Pend-X version), or omega loops can be placed within the TMA springs.<sup>12</sup>

Considerable research has been conducted on the Pendulum, with results supporting its effectiveness in molar distalization.<sup>2,39-49</sup> Because of its potential side effects, however, the Pendulum, like other intra-arch devices, is contraindicated in patients with skeletal or dental open bites, high mandibular plane angles, excessive lower facial height, or proclined maxillary incisors.<sup>12,13</sup>

Bussick and McNamara added another dimension to the Pendulum literature by evaluating the dentoalveolar and skeletal effects of the appliance in patients at various stages of dental development and with high, neutral, or low mandibular plane angles.<sup>45</sup> After studying 101 patient x-rays from 13 different practitioners, they concluded that the Pendulum moved the maxillary first molars an average of 5.7mm distally, with 10.6° of distal tipping and .7mm of intrusion. The maxillary first premolars were moved 1.8mm mesially, with 1.5° of mesial tipping and 1mm of extrusion. Although lower anterior facial height increased by an average of 2.2mm, there was no significant difference among patients with high, neutral, or low mandibular plane angles. The authors concluded, “For maximum maxillary first molar distalization with minimal increase in lower anterior facial height, this appliance is used most effectively in patients with deciduous maxillary second molars for anchorage and unerupted perma-

ment maxillary second molars, although significant bite opening was not a concern in any patient in this study.<sup>2,45</sup>

In 2003, Burkhardt and colleagues compared the treatment effects of the Pendulum with those of the Herbst appliance.<sup>2</sup> The Pendulum group showed a slight downward and backward rotation of the mandible, as evidenced by a 1.2° opening of the mandibular plane angle, while the Herbst group exhibited a .35° closing of the mandibular plane angle. In the patients treated with the Pendulum appliance, the maxillary incisors were flared 2.8°, and the maxillary molars were moved 5.9mm distally, tipped 10° distally, and extruded 1.7mm. No statistically significant differences in mandibular growth were observed between the Herbst patients and the Pendulum patients.

## Conclusion

A number of similar fixed intra-arch devices have been developed for maxillary molar distalization. The literature on these appliances is extensive, and the data reported are often contradictory. A scientifically based systematic review in the form of a true meta-analysis would help the profession reach clinically applicable conclusions.<sup>50</sup>

## REFERENCES

1. Bolla, E.; Muratore, F.; Carano, A.; and Bowman, S.J.: Evaluation of maxillary molar distalization with the Distal Jet: A comparison with other contemporary methods, *Angle Orthod.* 72:481-494, 2002.
2. Burkhardt, D.R.; McNamara, J.A. Jr.; and Baccetti, T.: Maxillary molar distalization or mandibular enhancement: A cephalometric comparison of comprehensive orthodontic treatment including the Pendulum and the Herbst appliances, *Am. J. Orthod.* 123:108-116, 2003.
3. McNamara, J.A. Jr.: Components of Class II malocclusion in children 8-10 years of age, *Angle Orthod.* 51:177-202, 1981.
4. McNamara, J.A. Jr. and Brudon, W.L.: *Orthodontic and Orthopedic Treatment in the Mixed Dentition*, Needham Press, Ann Arbor, MI, 1993, p. 95.
5. Tulloch, J.F.; Phillips, C.; Koch, G.; and Proffit, W.R.: The effect of early intervention on skeletal pattern in Class II malocclusion: A randomized clinical trial, *Am. J. Orthod.* 111:391-400, 1997.
6. Kloehn, S.J.: Evaluation of cervical anchorage force in treatment, *Angle Orthod.* 31:91-104, 1961.
7. Balters, W.: Die Technik und Übung der allgemeinen und speziellen Bionator-Therapie, *Quintessenz* 15:77-85, 1964, as cited in McNamara, J.A. Jr. and Brudon, W.L.: *Orthodontics and Dentofacial Orthopedics*, Needham Press, Ann Arbor, MI, 2001.
8. Klein, P.L.: An evaluation of cervical traction of the maxilla and the upper first permanent molar, *Angle Orthod.* 27:61-68, 1957.
9. Kloehn, S.J.: Guiding alveolar growth and eruption of teeth to reduce treatment time and produce a more balanced denture and face, *Angle Orthod.* 17:10-33, 1947.
10. Kloehn, S.J.: Orthodontics—force or persuasion, *Angle Orthod.* 23:56-66, 1953.
11. McNamara, J.A. Jr. and Brudon, W.L.: *Orthodontics and Dentofacial Orthopedics*, Needham Press, Ann Arbor, MI, 2001.
12. Sfondrini, M.F.; Cacciafesta, V.; and Sfondrini, G.: Upper molar distalization: A critical analysis, *Orthod. Craniofac. Res.* 5:114-126, 2002.
13. McSherry, P.F. and Bradley, H.: Class II correction—Reducing patient compliance: A review of the available techniques, *J. Orthod.* 27:219-225, 2000.
14. Gianelly, A.A.; Bednar, J.; and Dietz, V.S.: Japanese NiTi coils to move molars distally, *Am. J. Orthod.* 99:564-566, 1991.
15. Gianelly, A.A.: Distal movement of maxillary molars, *Am. J.*

- Orthod. 114:66-72, 1998.
16. Miura, F., Mogi, M.; Ohura, Y.; and Karibe, M.: The superelastic Japanese NiTi alloy wire for use in orthodontics, Part III: Studies on the Japanese NiTi alloy coil springs, *Am. J. Orthod.* 94:89-96, 1998.
  17. Reiner, T.J.: Modified Nance appliance for unilateral molar distalization, *J. Clin. Orthod.* 26:402-404, 1992.
  18. Keles, A.: Maxillary unilateral molar distalization with sliding mechanics: A preliminary investigation, *Eur. J. Orthod.* 23:507-515, 2001.
  19. Pieringer, M.; Droschl, H.; and Permann, R.: Distalization with a Nance appliance and coil springs, *J. Clin. Orthod.* 31:321-326, 1997.
  20. Puente, M.: Class II correction with an edgewise-modified Nance appliance, *J. Clin. Orthod.* 31:178-182, 1997.
  21. Locatelli, R.; Bednar, J.; Dietz, V.; and Gianelly, A.: Molar distalization with superelastic NiTi wire, *J. Clin. Orthod.* 26:277-279, 1992.
  22. Gianelly, A.A.: *Bidimensional Technique: Theory and Practice*, GAC International, Central Islip, NY, 2000.
  23. Kalra, V.: The K-loop molar distalizing appliance, *J. Clin. Orthod.* 29:298-301, 1995.
  24. Jones, R.D. and White, J.M.: Rapid Class II molar correction using an open-coil jig, *J. Clin. Orthod.* 23:661-664, 1992.
  25. Gulati, S.; Kharbanda, O.P.; and Parkash, H.: Dental and skeletal changes after intraoral molar distalization with sectional jig assembly, *Am. J. Orthod.* 114:319-327, 1998.
  26. Haydar, S. and Üner, O.: Comparison of Jones Jig molar distalization appliance with extraoral traction, *Am. J. Orthod.* 117:49-53, 2000.
  27. Brickman, C.D.; Sinha, P.K.; and Nanda, R.S.: Evaluation of the Jones Jig appliance for distal molar movement, *Am. J. Orthod.* 118:526-534, 2000.
  28. Carano, A. and Testa, M.: The Distal Jet for upper molar distalization, *J. Clin. Orthod.* 30:374-380, 1996.
  29. Carano, A.; Testa, M.; and Siciliani, G.: The lingual distalizer system, *Eur. J. Orthod.* 18:445-448, 1996.
  30. Carano, A.; Testa, M.; and Siciliani, G.: The Distal Jet for uprighting lower molars, *J. Clin. Orthod.* 30:707-710, 1996.
  31. Bowman, S.J.: Modifications of the Distal Jet, *J. Clin. Orthod.* 32:549-556, 1998.
  32. Quick, A.N. and Harris, A.M.P.: Molar distalization with a modified Distal Jet appliance, *J. Clin. Orthod.* 34:419-423, 2000.
  33. Carano, A.; Testa, A.; and Bowman, S.J.: The Distal Jet simplified and updated, *J. Clin. Orthod.* 36:586-590, 2002.
  34. Karaman, A.I.; Basciftci, F.A.; and Polat, O.: Unilateral distal molar movement with an implant-supported Distal Jet appliance, *Angle Orthod.* 72:167-174, 2002.
  35. Bowman, S.J.: Class II combination therapy, *J. Clin. Orthod.* 32:611-620, 1998.
  36. Bowman, S.J.: Class II combination therapy (Distal Jet and Jasper Jumpers): A case report, *J. Orthod.* 27:213-218, 2000.
  37. Hilgers, J.J.: The Pendulum appliance for Class II non-compliance therapy, *J. Clin. Orthod.* 26:706-714, 1992.
  38. Hilgers, J.J. and Bennett, R.K.: The Pendulum appliance, Part II: Maintaining the gain, *Clin. Impress.* 3:6-9, 14-22, 1994.
  39. Ghosh, J. and Nanda, R.S.: Evaluation of an intraoral maxillary molar distalization technique, *Am. J. Orthod.* 110:639-646, 1996.
  40. Snodgrass, D.J.: A fixed appliance for maxillary expansion, molar rotation, and molar distalization, *J. Clin. Orthod.* 30:156-159, 1996.
  41. Byloff, F.K. and Darendeliler, M.A.: Distal molar movement using the Pendulum appliance, Part 1: Clinical and radiological evaluation, *Angle Orthod.* 67:249-260, 1997.
  42. Byloff, F.K. and Darendeliler, M.A.: Distal molar movement using the Pendulum appliance, Part 2: The effects of maxillary molar root uprighting bends, *Angle Orthod.* 67:261-270, 1997.
  43. Byloff, F.K.; Kärcher, H.; Clar, E.; and Stoff, F.: An implant to eliminate anchorage loss during molar distalization: A case report involving the Graz implant-supported Pendulum, *Int. J. Adult Orthod. Orthog. Surg.* 15:129-137, 2000.
  44. Scuzzo, G.; Pisani, F.; and Takemoto, K.: Maxillary molar distalization with a modified Pendulum appliance, *J. Clin. Orthod.* 33:645-650, 1999.
  45. Bussick, T.J. and McNamara, J.A. Jr.: Dentoalveolar and skeletal changes associated with the Pendulum appliance, *Am. J. Orthod.* 117:333-343, 2000.
  46. Joseph, A.A. and Butchart, C.J.: An evaluation of the Pendulum distalizing appliance, *Semin. Orthod.* 6:129-135, 2000.
  47. Keles, A. and Sayinsu, K.: A new approach in maxillary molar distalization: Intraoral bodily molar distalizer, *Am. J. Orthod.* 117:39-48, 2000.
  48. Chaqués-Asensi, J. and Kalra, V.: Effects of the Pendulum appliance on the dentofacial complex, *J. Clin. Orthod.* 35:254-257, 2001.
  49. Kinzinger, G.; Fritz, U.; and Diedrich, P.: Combined therapy with Pendulum and lingual arch appliances in the early mixed dentition, *J. Orofac. Orthop.* 64:201-213, 2003.
  50. Jones, D.R.: Meta-analysis of observational epidemiological studies: A review, *J. R. Soc. Med.* 85:165-168, 1992.